

Intestinal Protozoa Detection: Assessment of the Artificial Intelligence (AI)-based Techcyte Platform

Bao JR, Master, RN, Jones RS, Clark RB, Caldwell, LM, Shier KL
Quest Diagnostics Nichols Institute, Chantilly, VA 20151

Introduction

- Intestinal protozoa infections are a significant contributor to gastrointestinal illness worldwide.
- Laboratory diagnostics of infections using manual microscopic ova-and-parasite examination (O&P) of stool specimens is still the gold standard, even though antigen-based testing is largely available for the major important intestinal protozoa.
- The disadvantages of the manual O&P method are noticeable, including labor, variable sensitivity, and need of personnel expertise. Delayed turnaround of quality laboratory reports has become clinically significant and the shortage of skilled technologists for O&P tests has increased over years. There is a pressing need for new tools to assist technologists in performing the O&P examinations.
- Recent advances in artificial intelligence (AI)-based technology provide the potential to reduce the laborious manual procedures, while providing sensitive detection for O&P exams.
- In this study, we evaluated an AI-based detection platform developed by Techcyte (Lindon, Utah) for possible application in a clinical laboratory's intestinal protozoan examination.

Methods

- The Techcyte platform (Lindon, Utah) pairs a panoramic automatic slide scanner (P250 Flash III, 3Dhistech, Hungary) with a deep-learning-based convolutional neural network (CNN) model for data interpretation. The CNN model was developed by Techcyte to label and interpret the scanned digital images for intestinal protozoa identification.
- The platform was set for auto-feeding of slides, digital scanning and data processing according to the developer's instructions and parameters.
- A successful resulting profile had about 80% of the scanning area (3.8×10.2 mm area) in focus and analyzed by software. An indeterminate result had a blurry image.
- Two trichome-stained stool specimen slides were prepared from each of the remnants of deidentified patient samples representing a variety of intestinal protozoa.
- The stool specimens were taken from Total-Fix® or polyvinyl alcohol-preserved stool sediments. The fixed sediment for slide preparation was lightly diluted by adding saline to about 25% of the sediment to control specimen thickness on slides for better scanning results. All the other procedures for sediment centrifugation, slide preparation and trichome-staining were performed according to the laboratory protocols.

Methods (continued)

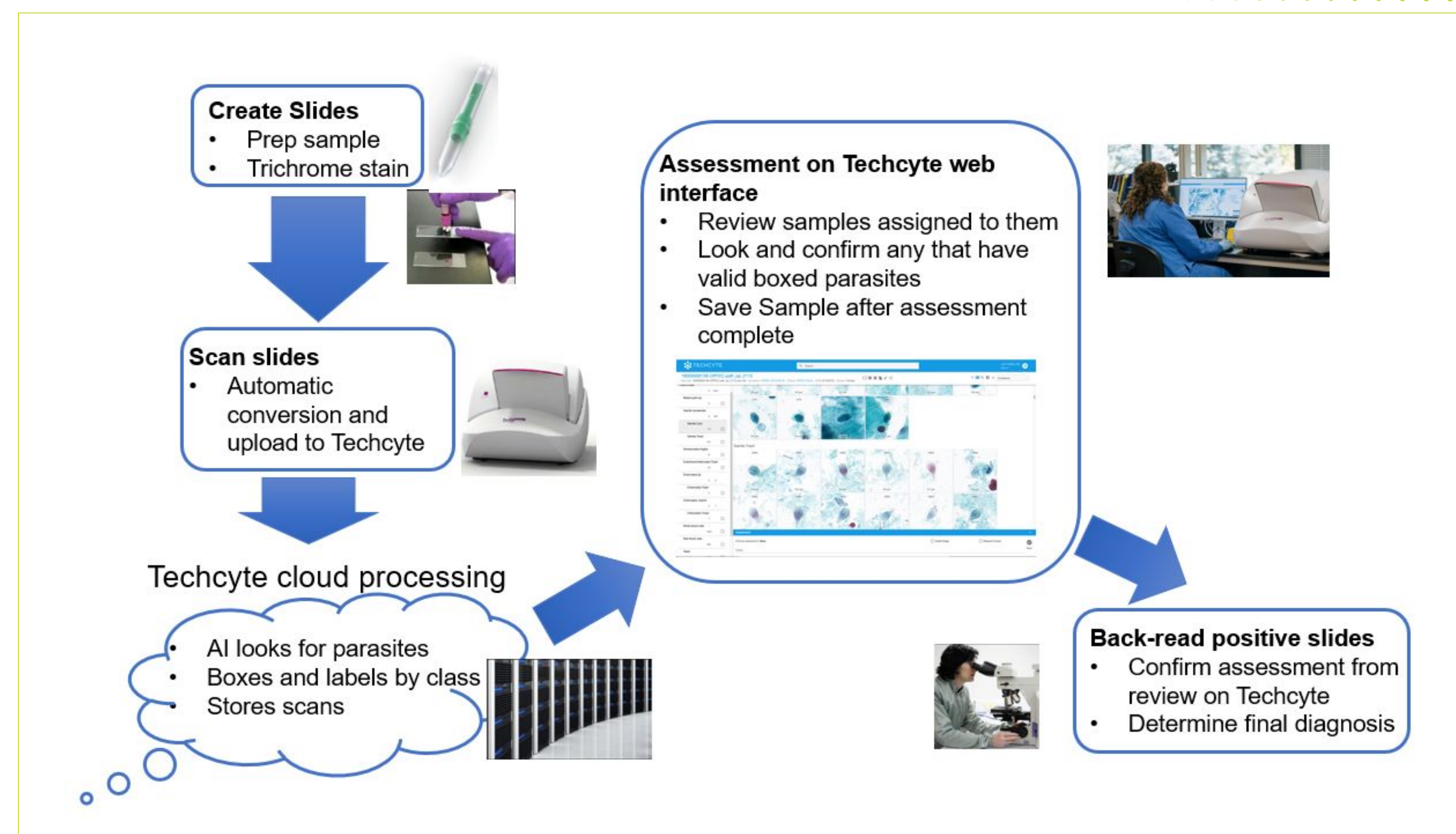


Figure 1. Basic workflow of the intestinal protozoa detection using the AI-based Techcyte platform (Edited from Techcyte presentation, with permission).

- Of the two slides prepared from each specimen, one slide was examined using a manual microscopic method as the reference and the other was scanned on the Flash III under 40x objective lens. The scanned digital image data were fed on-line to the CNN model for result interpretations (**Figure 1**).
- Positive digital images for intestinal protozoa were reviewed directly on screen by a technologist and the discrepant or indeterminate slides were re-examined by a manual microscopic method. All the results from the AI-based method were compared to the manual microscopic method.

Results

- Among the total 665 paired slides prepared and examined, the Techcyte platform identified 132 positives, 519 negatives, and 14 invalids (**Table 1**).

Table 1. Comparison of microscopic and Techcyte methods for protozoan detection results

Interpretation	Microscopic Method	Techcyte Method	
		CNN Model Screen Result	Manual Microscopy Confirmed Result
Positive	78	132	80
Negative	587	519	583
Invalid	0	14	2
Total slides	665	665	

- For the positives by the Techcyte method, 80 were confirmed as true positives, including 78 positives by both methods and 2 missed by manual microscopy. The remaining slides (52 positive and 14 invalid) were confirmed as 64 negatives and 2 unconfirmed due to poor slide quality.

Results (continued)

- The scanned images from successful resulting profiles with confirmed results typically had good resolution and had the intestinal protozoa confirmed directly from the computer screen (**Figure 2**).
- The protozoan types, including *Cyclospora* species, identified by the Techcyte system were in concordance with the reference method (**Table 2**).
- Confirmation of the organism identification was required and acquired via manual observation from either reviewing images on screen or a microscopic examination.
- It took about 4.5 minutes per slide on average to complete the scanning. Continual slide reading on the scanner with auto-feeding could save labor time in the future.

Table 2. Organisms detected correctly on the Techcyte platform

Fixing medium	Organism	Number of Slides
Total Fix®	<i>Blastocystis</i> sp.	10
	<i>Chilomastix mesnili</i>	5
	<i>Dientamoeba fragilis</i>	10
	<i>Endolimax nana</i> / <i>Iodamoeba buetschlii</i>	9
	<i>Entamoeba hartmanni</i>	5
	<i>Giardia duodenalis</i> cyst/trophozoite	10
	<i>Entamoeba coli</i>	10
	<i>Entamoeba</i> sp. (<i>E. histolytica/dispar</i>)	10
	<i>Giardia lamblia</i> / <i>Entamoeba</i> sp.	1
	<i>G lamblia</i> / <i>Dientamoeba fragilis</i>	1
	<i>Blasto.</i> / <i>Entamoeba</i> sp. / <i>E. coli</i>	1
	<i>Blasto.</i> / <i>E. nana</i> / <i>E. hartmanni</i> / <i>I. buetschlii</i>	1
	<i>Blasto.</i> / <i>E. hartmanni</i>	1
Polyvinyl alcohol	<i>G duodenalis</i> cyst / trophozoite	1
	<i>G duodenalis</i> cyst / trophozoite	1
	<i>G duodenalis</i> cyst / trophozoite	1
	<i>D fragilis</i>	1
	<i>Entamoeba hartmanni</i>	1
Total	<i>Cyclospora</i> sp.	1
		80

Results (continued)

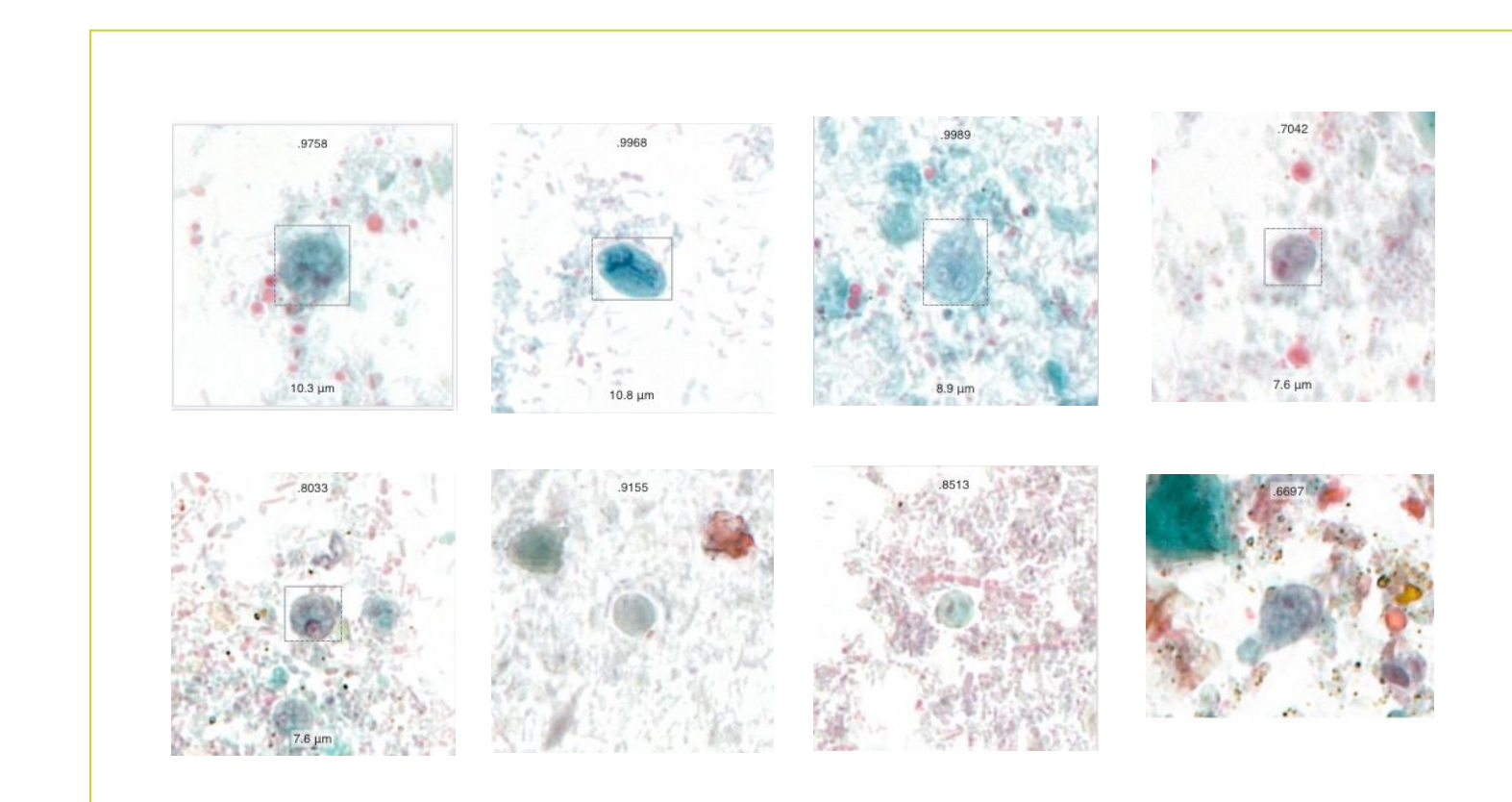


Figure 2. Representative images from trichome-stained slides by the Flash III scanner (from Techcyte, with permission).

Conclusions

- The AI-based platform is a robust and sensitive method to screen protozoa semi-automatically in stool samples.
- The screening software's prioritization of sensitivity over specificity required a confirmatory read for positives.

References

- Mathison BA, Kohan JL, et al. 2020. Detection of intestinal protozoa in Trichrome-stained stool specimens by use of a deep convolutional neural network. *J Clin Microbiol.* 58:e02053-19. doi:10.1128/jcm.02053-19
- McHardy IH, Wu M, et al. 2014. Detection of intestinal protozoa in the clinical laboratory. *J Clin Microbiol.* 52:712-720. doi:10.1128/jcm.02877-13

Acknowledgments

We thank Mr. John Walker of Techcyte for technical assistance, and several Quest Diagnostics laboratories, especially Quest Valencia, CA for some specimen collections. We thank Drs. Andrew Hellman, Hema Kapoor, Hollis Batterman, and Steven Taylor of Quest for their critical comments.